

Case Report

EWING SARCOMA FAMILY OF TUMORS OF SCAPULA IN CHILDREN

Dragoljub Živanović^{1,2}, Zoran Marjanović^{1,2}

¹University of Niš, Faculty of Medicine, Niš, Serbia

²Clinic for Pediatric Surgery, Orthopedics and Traumatology, University Clinical Center Niš, Serbia

Abstract. *Ewing's sarcoma (ES) is the second most common malignant bone tumor accounting for 5-10% of malignancies in childhood. The scapula is rarely affected and only several reports have been published. Early symptoms of Ewing's sarcoma of the scapula may be ignored by patients or misinterpreted by physicians, leading to a delay in diagnosis. In the retrospective analysis, we identified 3 patients (2 males) with Ewing's sarcoma of scapula, aged 11 - 14½ years in a 15-year period. The introduction of combined treatment with multimodal chemotherapy, surgical resection and/or radiation therapy has improved the survival of patients with Ewing's sarcoma significantly. Several options for resection of ES of scapula were described with generally unfavorable functional results. Two patients were treated with chemotherapy and resection of the scapula. The third patient is on chemotherapy. Two patients died after 2½ and 4 years. In children and adolescents presenting with shoulder pain, Ewing's sarcoma must be ruled out.*

Key words: *Ewing's sarcoma; PNET; scapula; children, diagnosis, treatment, bone cancer*

Introduction

Ewing sarcoma of bone (ES), extraskeletal Ewing sarcoma, primitive neuroectodermal tumors of bone and soft tissue (PNET) and Askin tumor are malignant tumors known under the common name Ewing sarcoma family of tumors (ESFT) [1] because they share many common characteristics. Ewing sarcoma is the second most frequent malignant bone tumor in children and adolescents after osteosarcoma and accounts for about 5-10% of bone malignancy in childhood [2]. The reported incidence of ES is 2.5-3 cases per million per year [1, 3]. Slight male predominance has been reported [4]. Ewing sarcoma exhibits marked racial difference in incidence. It most frequently occurs in Caucasians [4, 5] and is uncommon in Black and Chinese children. Although ESFT may occur at any age the peak incidence is between 10 and 15 years, but almost 30% of patients are younger than 10 [6]. Occasionally ESFT may occur in children younger than 5 and in adults over 30 years [1, 7]. Most of the ESFT tumors arise in diaphyseal or meta-diaphyseal regions of long bones followed by the pelvis, ribs and spine [1, 8]. Other less frequent locations include the skull, scapula and small bones of hands and feet [2, 9]. In contrast to other malignant primary tumors of bone, about 20% of ESFT develop in soft tissues [1, 2]. The delay between onset of symptoms and definitive diagnosis is common [10]. At the time of the diagnosis 15-50 % of patients have distant metastases and 5 % have metastases in regional lymph nodes [4, 7, 11]. The most common sites of metastases are lungs, bones and bone marrow or a com-

ination thereof. Primary bone tumors localized in the scapula are generally rare. They are more likely to be malignant than benign [12]. Tumors of the scapula usually grow significantly before the definitive diagnosis. In the beginning tumors are usually concealed within surrounding muscles. The early symptoms are often attributed to physical or sport activities, growth or trauma. In 2011 Shahid found less than 15 published cases of ES of scapula [12].

The Aim

The aim of our study is to present three cases of ESFT in children with a primary location in the scapula.

Materials and Methods

We performed a retrospective database search for the patients diagnosed with ESFT of the scapula in the period 2001-2016. Three patients have met the inclusion criteria. Patients' data, imaging studies including ultrasound, x-rays and MRI, laboratory findings, histopathology reports, treatment and outcome of treatment were analyzed.

Results

In the fifteen-year period, ESFT of scapula was diagnosed in three patients, two boys and one girl. The mean age was 11.3 years. The right scapula was involved in two and the left in one patient.

A summary of the patients is given in Table 1.

Correspondence to: Dragoljub Živanović
Clinic for Pediatric Surgery, Orthopedics and Traumatology,
University Clinical Center Niš, Serbia,
Dr. Zorana Dindjica Blvd 48, 18000 Niš, Serbia
E-mail: dzivanovic.nis@gmail.com
Received August 19th, 2022 / Revised September 29th, 2022 /
Accepted September 30th, 2022

Case #1

Eleven and a half years old boy was referred to pediatric surgeon by a pediatric hematologist. Initially, he presented to pediatrician with cervical lymphadenopathy several weeks earlier. When a palpable mass in his left scapular region had been discovered by a hematologist, he was referred to pediatric surgeon. On physical examination swelling in the left scapular region was obvious. The overlying skin was erythematous, without an increase of local temperature. The swelling was solid and painful on palpation. The mass was not mobile in relation to a deep underlying structures. Shoulder motion was unrestricted. There were palpable cervical lymph nodes along the left sternocleidomastoid muscle. The boy had no previous history of night pain or excessive sweating. His previous medical history was unaltered. His erythrocyte sedimentation rate (ESR) was elevated (42/72), but RBC ($4.15 \times 10^6/\mu\text{L}$), WBC ($9.4 \times 10^3/\mu\text{L}$) and hemoglobin (10.5g/dL) were within physiological ranges. Alkaline phosphatase (ALP) level of 545 mmol/L was within normal range for his age (0,000-650 mmol/L), but lactate dehydrogenase (LDH) level was elevated to 510 U/L (normal range 200-400 U/L). All other biochemical tests were within normal ranges. The abdominal ultrasound was normal. An ultrasound of left shoulder region revealed solid lobulated inhomogeneous mass whose dimensions were 35 x 31 mm (Fig. 1). The tumor was located in soft tissues of suprascapular region, adjacent to bone. The mass had highly developed arterial and venous vascularization. Next to dorsal surface of tumor thin layer of fluid was visible. Computed tomography (CT) showed irregular, ovoid, inhomogeneous tumorous formation in left suprascapular region that extended to lateral border of acromion. Mass was hypo-dense with attenuation values of 42 HU. Acromion appeared osteoporotic, with destructed bone morphology. The tumor showed a relatively clear margin to surrounding soft tissues. After the application of contrast, intensive uptake was observed with an increase in attenuation values for approximately 10-15 HU. CT-scan was suggestive of a highly vascularized tumor of the left scapular region. The

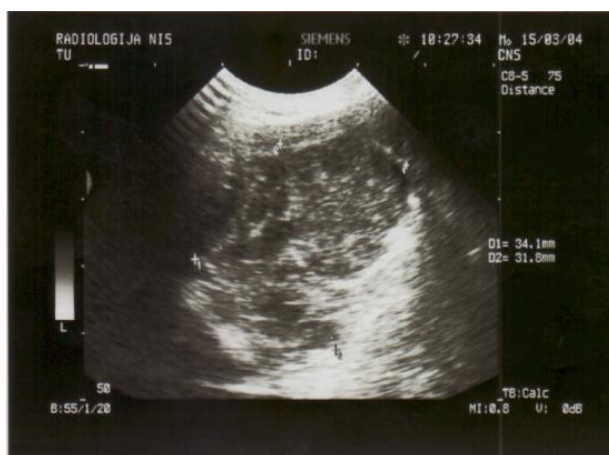

Fig. 1 Inhomogeneous, ill-defined, ultrasound appearance of ES of scapula (Case 1) measuring 34 x 31 mm.

patient was prepared and operated on. Resection of tumor along with the whole acromion and part of the scapula was performed with wide margins. Resected tumor measured 7 x 4 x 3.5 cm. On histology tumor was composed of small dense uniform round cells with round nuclei and scarce cytoplasm and the histopathology diagnosis was Ewing's sarcoma. Chest x-ray and CT scan didn't show pulmonary metastasis. The patient was then referred to the national oncology center where he received multimodal adjuvant chemotherapy. He was doing well for three years postoperatively. Then pulmonary metastases have been detected and he succumbed four years after surgery.

Case #2

A fourteen-and-a-half-year-old girl presented with swelling and pain in her right shoulder. Four months earlier she had begun to feel pain in shoulder region. The pain was intermittent and present during day only. She went to a primary care physician and was referred to physiotherapy. During the manual massage which was very painful mild swelling in the right scapular region was noticed. Physiotherapy was discontinued and she was prescribed rest, oral and topical analgesics. Since the pain became constant, with the increased intensity especially during the night she was referred to a pediatric surgeon. On the initial clinical examination the swelling of the right scapular region was observed. The overlying skin looked normal. On palpation the tumor appeared solid and poorly defined from surrounding soft tissue. The mass was painful on palpation with no mobility in relation to underlying structures or overlaying skin. The ultrasound revealed poorly defined, inhomogeneous mass within the soft tissue of scapular region (Fig. 2A). On plain X-ray the bone structure of right scapula appeared irregular and mottled (Fig. 2B). The patient was admitted for further laboratory tests and MRI. The blood count was normal, but ESR was elevated (57/85). In blood biochemistry elevated levels of alkaline phosphatase (722 mmol/L; normal range 0,000-650 mmol/L) and lactate dehydrogenase (658 U/L; normal range 200-400 U/L) were observed. Other parameters including liver and renal function were within normal ranges for age. MRI revealed expansive tumor formation which had infiltrated body and spine of right scapula also infiltrated supraspinatus, infraspinatus and subscapularis muscles (Fig. 2C-F). No infiltration of chest wall was demonstrated.

Open biopsy of the tumor was performed. The histology confirmed tumor composed of small round cells with round nuclei and one nucleolus with a very small cytoplasm. The diagnosis of Ewing's sarcoma had been established and confirmed by immunologic studies performed in another laboratory. Disseminated pulmonary metastases were noticed on chest CT scan. The patient was referred to the national oncology center for multimodal chemotherapy protocol. After 6 cycles of neoadjuvant chemotherapy scapulectomy was performed followed with postoperative chemotherapy. She died 2½ year after the diagnosis.

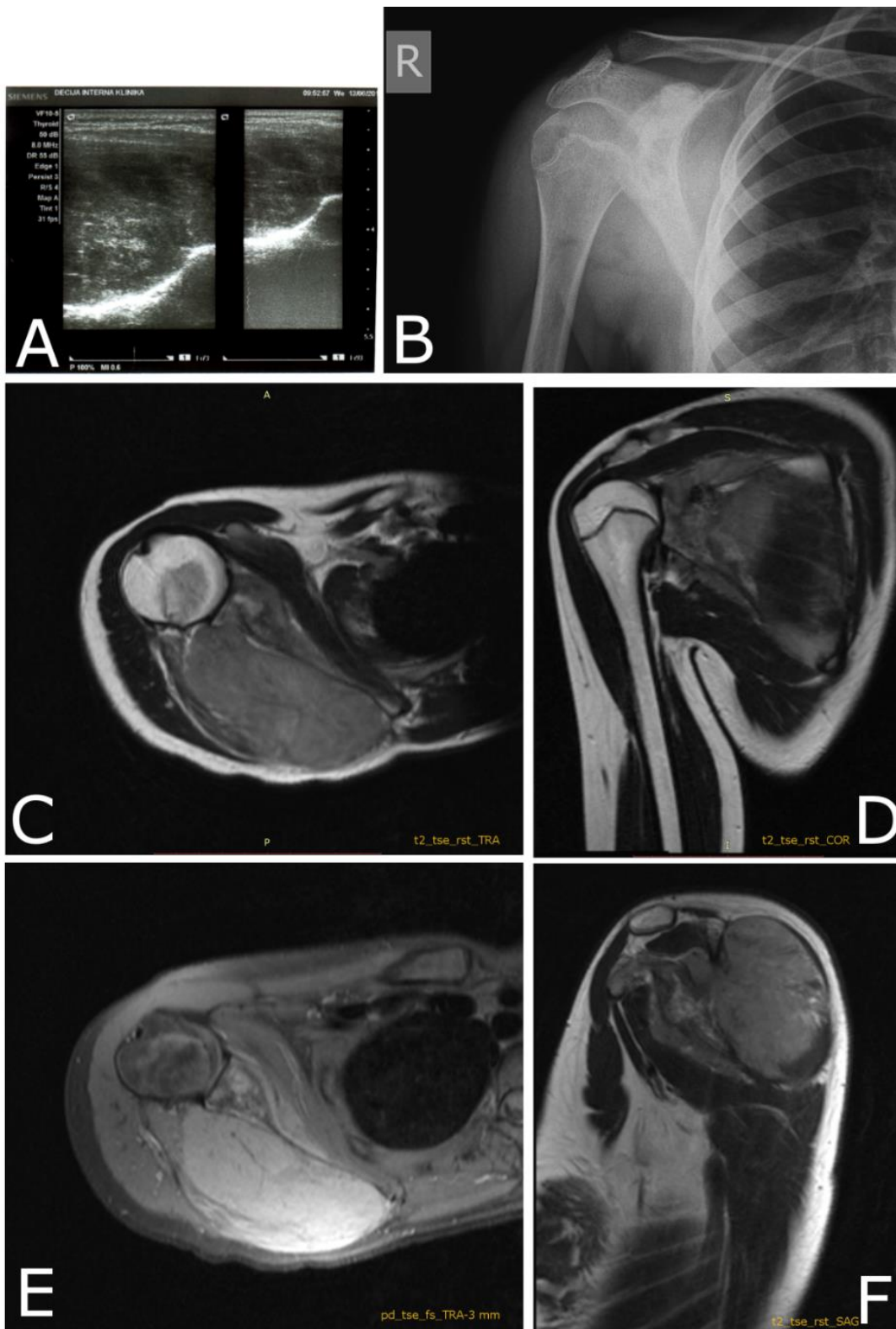


Fig. 2 A) Inhomogeneous mass on ultrasound of right scapular region (Case 2). B) Plain X-ray of right scapula with permeative lesions without sclerosis. C-F) MRI findings of the same patient. C) Large soft tissue mass on transverse section. D) Infiltration of body of scapula and subscapularis muscle on coronal section. E) Bone and muscular infiltration on transverse f-stir section and F) sagittal section.

Case #3

An eleven year old boy was referred from the community regional hospital on an emergency basis because of suspected phlegmon in the right scapular region. A month earlier, after minor trauma (he was hit by another boy during the school skirmish) he felt pain in the right shoulder. The swelling occurred on the next day. The diagnosis of contusion was established by a primary care physician. Rest, topical analgesics and oral painkillers were prescribed. Nevertheless, swelling and pain increased boy became febrile, and he was admitted to the local pediatric department where he was treated with IV antibiotics for 4 days. His condition had worsened despite therapy and he was transferred to a tertiary level institution. On admission, the patient was sub-febrile (37.8°C) and complained of severe pain. Clinically, swelling in the right scapular region was obvious. The skin was erythematous with increased local temperature. Movements in the right shoulder were painful and reduced to about half of the normal range. The erythrocyte sedimentation rate was elevated to 40/80. Blood tests showed normal levels of WBC and RBC, a slight decrease in hemoglobin level

(119g/L) and thrombocytosis of $424 \times 10^9/\text{L}$. Levels of ALP and LDH were within normal ranges (152 U/L and 383U/L respectively). Other biochemical parameters were normal, except the elevated level of C-reactive protein (112.05 mg/L , normal range $0.00\text{-}0.5$). The abdominal ultrasound was normal. On ultrasound examination of the right scapular region two inhomogeneous, poorly delineated, expansive masses approximately $19 \times 9\text{ mm}$ and $35 \times 20\text{ mm}$ in diameter were detected within muscles (Fig. 3A). Color Doppler revealed intense peripheral vascularization of tumor tissue. On plain x-ray's right scapula appeared inhomogeneous, with permeative bone destruction, especially along the superior half of the medial border and infraspinous fossa (Fig. 3B). MRI of the right shoulder region was performed. An expansive tumor that infiltrated the body, spine and part of the acromion of the right scapula was found. Supraspinatus, infraspinatus, subscapularis and trapezius muscles also were infiltrated. After the application of contrast an intense, inhomogeneous increase in signal occurred (Fig.3C and D). Numerous lymph nodes were detected in the suprascapular region and in the right axilla. No in-

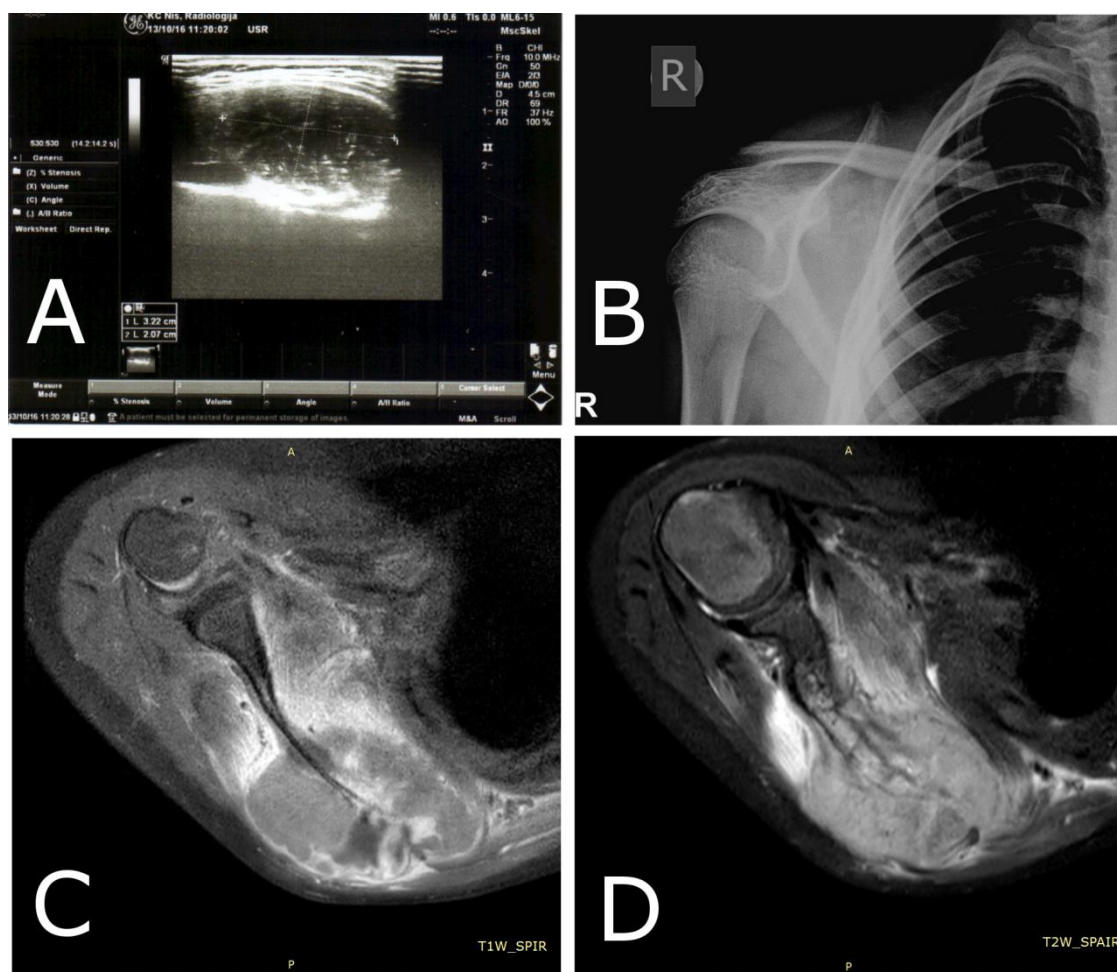


Fig. 3 A) Inhomogeneous ultrasound appearance of ESFT (Case 3.) B) Plain X-ray shows irregular, moth-eaten bone structure of right scapula in upper and medial part. C) Tumor infiltrating subscapularis and supraspinatus muscle is visible on transverse MRI T1W section. D) Infiltration of body of scapula and muscles by tumor is noticeable on transverse T2W MRI sequence.

Table 1 Patients overview.

	Case 1	Case 2	Case 3
Time from onset of symptoms to diagnosis	4 weeks	4.5 months	4 weeks
Leading symptom	Cervical lymphadenomegaly	Pain	Swelling and pain
Laboratory findings			
ESR*	Elevated (42/72)	Elevated (57/85)	Elevated (40/80)
ALP [#]	Normal (545)	Elevated (722)	Normal (152)
LDH [§]	Elevated (510)	Elevated (658)	Normal (383)
Histopathology	Ewing sarcoma	Ewing Sarcoma	ESFT PNET
Immunohistochemistry		CD99 ⁺ , Vimentin ⁺ FLI1 ⁺	CD99 ⁺ , Vimentin ⁺ FLI1 ⁺ Synaptophysin ^{+/-} CD56 ^{+/-}
Metastases at presentation	No	Yes, pulmonary	No
Preoperative chemotherapy	No	6 cycles	4 cycles
Surgery	Wide resection	Scapulectomy	-
Survival	4 years	2.5 years	Lost for follow/up

*ESR – erythrocyte sedimentation rate

[#]ALP – alkaline phosphatase

[§]LDH – lactate dehydrogenase

involvement of chest structures, humerus and clavicle has been observed. Open biopsy and bone marrow aspiration was performed under general anesthesia. Histopathology showed tumor composed of small, round, hyperchromatic cells with scant cytoplasm and one nucleolus in a round nucleus. Tumor cells were organized in sheets with the focal formation of pseudo-rosettes. Immunohistochemistry demonstrated cells positive on CD99, vimentin, and FLI-1, partially positive on synaptophysin and CD56 and negative on desmin, myogenin, chromogranin and LCA. Bone marrow aspirates were normal. No pulmonary metastases were noted on chest CT scans. The boy was referred to the national oncology center for chemotherapy protocol. He received four cycles of chemotherapy until he was lost for further follow-up.

Discussion

Ewing sarcoma is highly malignant primary bone tumor, composed of uniform round small cells with round nuclei and scant cytoplasm. Tumor cells produce no matrix. Cytoplasm is (PAS+) [2] because of glycogen content. Ewing sarcoma is frequently associated with translocations resulting in fusion transcript EWS-FLI [13] or EWS-ERG [14]. This is crucial in tumorigenesis, transdifferentiation into characteristic small round cell phenotype and neural marker expression [2]. This common genetic profile of several small round cell tumors is now grouped under entity Ewing Sarcoma family of tumors – ESFT with poorly differentiated ES on one and more differentiated PNET lying on the other end. This family of tumors shares the same neurogenic cell of origin as was demonstrated on electron microscopic and immunohistochemical studies [4]. Two tumors in our series exhibit typical histological features of small round cell ES and the third tumor demonstrates signs of neurological differ-

entiation characteristic for PNET. Immunohistochemical positivity for CD99, vimentin and FLI1 is detected in majority of ESFT. In more differentiated PNET tumors positivity for neuron-specific enolase (NSE), synaptophysin, S-100, Leu-7(CD57) and/or PGP 9.5 may be demonstrated [2, 4, 10]. Two of our cases were positive for CD99, vimentin and FLI1, and one of them also showed partial immunoreactivity for synaptophysin and CD56. For the third case we could not obtain immunohistochemistry data.

Peak incidence of ESFT in the second decade of life coincides with an increase in the secretion of insulin-like growth factor 1 (IGF-1) and the sensitivity to IGF-1 receptor inhibition is the hallmark of ESFT. All our patients were in the first half of the second decade of life at the presentation.

The majority of ESFT arises in long bones of the lower extremity, pelvis, chest wall and spine [1] but up to 20% may develop in soft tissue. Malignant tumors of the scapula are generally rare and include chondrosarcoma, synovial sarcoma, Ewing sarcoma (ES) and metastasis [15]. Reports of ESFT of the scapula are scarce [12, 15-18]. The earliest symptom of ESFT in the majority of patients is pain, mild and intermittent in the beginning but with a gradual increase in intensity over time. The onset of night pain should always be considered as a warning sign that requires further investigation [8]. The pain localized in the scapula may be erroneously attributed to various conditions like overuse syndrome, growth-related pain, or trauma in patients with ESFT. Our patients had mild pain at early stages which increased over time. In all of them the pain was initially attributed to different causes such as cervical lymphadenomegaly in the first, overuse in the second and trauma in the third patient. In the second and third patient the pain was of such intensity at presentation that it could not be relieved by oral analgesics. ESFT typically grows fast and may become quite

large within several weeks. In specific locations, where tumor is confined within muscles, covered with large soft tissue layer or it grows in cancellous bone or medullary canal without penetrating the cortex [19] it may take several months or even year until it becomes visible or palpable. The interval from the onset of symptoms to the diagnosis of ESFT decreased from 9.6 months in 1984 to 4.7 months in 2003 [4] but delay in the diagnosis of 3 to 6 months is not uncommon. In two of our patients duration of symptoms was relatively short (6 and 4 weeks in cases 1 and 3 respectively) but it could be shortened for 2-3 weeks if bone tumor had been included in differential diagnoses. In the third patient, (case 2) the time from the onset of symptoms to the moment of establishing the diagnosis was 4.5 months, because her symptoms were attributed to the overuse syndrome, despite the night pain. The delay in establishing the diagnosis could be doctor-related – the wrong diagnosis on presentation based on clinical or ultrasound findings; or patient related – usually painless mass that is ignored [20]. Although the diagnosis of ESFT in our patients was established within expected time frame, every effort should be made in order to maximally reduce unnecessary time loss in those patients. Some patients with ES may have fever. Only one patient in our group had fever (case 3), initially misinterpreted as a consequence of infection of the posttraumatic hematoma. The erythrocyte sedimentation rate is usually elevated, as was the case in all our patients. The patients with ES also may have anemia and leukocytosis [4, 19] but these parameters were normal in our group of patients. High values of ALP and LDH may be observed. Elevation of their levels is the unfavorable prognostic factor, as was in the first two of our cases.

The initial imaging study should be plain X-rays. In long bones, ES has typical radiologic picture of an ill-defined diaphyseal and/or metaphyseal destructive lesion with onion skin-like appearance and periosteal reaction but in flat bones of pelvis or scapula identification of ES could be difficult [4]. Ewing's sarcoma of scapula usually has a permeative, moth-eaten appearance with little or no bone sclerosis on plain X-rays [12] which was clearly visible in our patients (Fig. 2B and 3B). The next step in the imaging should be MRI [19]. On MRI Ewing's sarcoma appears as an extraskelatal mass derived from bone that exhibits low signal intensity on T1-W and high signal intensity on T2-W sequences [4]. If MRI is contraindicated CT should be performed. For the detection of pulmonary metastases, CT scans are the most appropriate imaging modality. For the detection of skeletal metastases, whole body scintigraphy is often used. Recently, it has been demonstrated that F-18-deoxy-d-glucose positron emission tomography (18FDG-PET) may be sufficient for initial detection of bone metastases and bone marrow involvement [21]. In the first patient CT scan was performed because of temporary unavailability of MRI. In the other two patients (cases 2 and 3), MRI showed tumor that infiltrated scapula with large soft tissue mass expanding in subscapularis, supra- and infraspinatus muscles (Fig. 2C-F and Fig. 3C&D). Ultrasound

may have misleading role in diagnostics of ESFT. The primary value of US is in visualization of soft tissue mass (Fig. 1A, 2A and 3A), and if it appears as highly vascularized lesion on color Doppler the patient should be referred to the institution accredited for the treatment of such tumors without any delay [8]. Abdominal ultrasound is recommended as a part of full diagnostic workup.

In all 3 children, the open incisional biopsy was performed for adequate tissue sampling [19], although fine needle aspiration biopsy and core needle biopsy may be performed as well [2]. Modern treatment of ESFT includes multimodal systemic chemotherapy and local control of tumor by surgery and/or radiotherapy [8]. The role of preoperative neoadjuvant chemotherapy is to eradicate distant micrometastases and reduce tumor volume to facilitate its resection [4]. Although amputation was the only surgical option for decades, current surgical management of ESFT includes limb salvage procedures with tumor resection and reconstruction [19]. Wide margins should be the goal of surgical resection in ESFT as is in all other high-grade malignancies. Surgical options for malignant bone tumors of the scapula include total scapulectomy, constrained prosthesis and allograft [17]. Subtotal scapulectomy with glenothoracic fusion has been developed to improve shoulder function [22]. Hoornenborg et al. recently described the treatment of ES of the scapula in a 9½ year-old boy with resection, extracorporeal irradiation and re-implantation with good results [15]. Once radiation therapy was the primary method of local control. Currently, it plays a role in patients with inoperable tumors, tumors that were resected within unsafe margins or if the response to chemotherapy was inadequate [4]. When the possibility of achievement of wide margins is uncertain, preoperative irradiation may be added to the treatment [19]. Wide resection of tumor was accomplished by subtotal scapulectomy in one of our patients (case 1). He didn't receive preoperative chemotherapy. In the second patient (case 2), after 6 cycles of preoperative neoadjuvant chemotherapy scapulectomy was performed. The third patient had received 4 cycles of chemotherapy before he was lost for follow-up.

Several factors are associated with unfavorable prognosis of ESFT: location in axial skeleton, size of tumor > 8 cm, elevated serum LDH, patients older than 14 years, inadequate or no surgical resection of the tumor and poor response to preoperative chemotherapy, but the presence of metastatic disease at the time of diagnosis remains strongest adverse prognostic factor [1, 8]. The five-year survival for ESFT patients treated with surgery or radiation alone is less than 10%. The adjunct of aggressive multimodal chemotherapy improved the 5-year survival to 60-70% in patients with localized and 20-40% in cases of metastatic disease [4, 19]. Both patients with poor outcome in our study had elevated LDH, large tumors (7 and 9.5 cm) and unfavorable location of tumor in scapula. One patient was older than 14 years and had pulmonary metastases and the another one had tumor resection without preoperative chemotherapy. The third patient has no adverse prognostic factors.

In the children in the second decade of life presenting with the pain in the scapular region, the intensity of which gradually increases and especially if it appears overnight, ESFT should always be considered as a potential diagnose. Visible and palpable mass may appear later. Elevated ESR, ALP and LDH are common finding. Ultrasound is usually misleading. Although a moth-eaten appearance of the scapula is characteristic X-ray finding, MRI is necessary for establishing the diagnosis. Histopathology and immunohistochemical analysis of biopsy material confirms diagnosis of ESFT. All patients with suspected ESFT of scapula should be referred to the appropriate center for further diagnosis and therapy without any delay. Neoadjuvant chemotherapy along with surgical resection and radiation therapy in selected cases increases the chance of survival. Metastatic disease at the time of diagnosis remains the most important prognostic factor for the unfavorable outcome.

References

- Jackson TM, Bittman M, Granowetter L. Pediatric Malignant Bone Tumors: A Review and Update on Current Challenges, and Emerging Drug Targets. *Curr Probl Pediatr Adolesc Health Care*. 2016; 46(7):213-228. doi: 10.1016/j.cppeds.2016.04.002
- Desai SS, Jambhekar NA. Pathology of Ewing's sarcoma/PNET: Current opinion and emerging concepts. *Indian J Orthop*. 2010; 44(4):363-368. doi: 10.4103/0019-5413.69304
- Kaatsch P, Strothotte J, Becker C, Bielack S, Dirksen U, Blettnner M. Pediatric bone tumors in Germany from 1987 to 2011: incidence rates, time trends and survival. *Acta Oncol*. 2016; 55(9-10):1145-1151. doi: 10.1080/0284186X.2016.1195509
- Ozaki T. Diagnosis and treatment of Ewing sarcoma of the bone: a review article. *J Orthop Sci*. 2015; 20(2):250-263. doi: 10.1007/s00776-014-0687-z
- Lahl M, Fisher VL, Laschinger K. Ewing's sarcoma family of tumors: an overview from diagnosis to survivorship. *Clin J Oncol Nurs*. 2008; 12(1):89-97. doi: 10.1188/08.CJON.89-97
- Wong T, Goldsby RE, Wustrack R, Cash T, Isakoff MS, DuBois SG. Clinical features and outcomes of infants with Ewing sarcoma under 12 months of age. *Pediatr Blood Cancer*. 2015; 62(11):1947-1951. doi: 10.1002/pbc.25635
- De Ioris MA, Prete A, Cozza R, et al. Ewing sarcoma of the bone in children under 6 years of age. *PLoS One*. 2013; 8(1):e53223. doi: 10.1371/journal.pone.0053223
- Gerrand C, Athanasou N, Brennan B, et al; British Sarcoma Group. UK guidelines for the management of bone sarcomas. *Clin Sarcoma Res*. 2016; 6:7. doi: 10.1186/s13569-016-0047-1
- Shirley SK, Askin FB, Gilula LA, et al. Ewing's sarcoma in bones of the hands and feet: a clinicopathologic study and review of the literature. *J Clin Oncol*. 1985; 3(5):686-697. doi: 10.1200/JCO.1985.3.5.686
- Bernstein M, Kovar H, Paulussen M, et al. Ewing's sarcoma family of tumors: current management. *Oncologist*. 2006; 11(5):503-519. doi: 10.1634/theoncologist.11-5-50
- Asif N, Khan AQ, Siddiqui YS, Mustafa H. Metastasis from scapular Ewing's sarcoma presenting as sutural diastasis: An unusual presentation. *Int J Shoulder Surg*. 2010; 4(1):18-21. doi: 10.4103/0973-6042.68415
- Shahid M, Varshney M, Maheshwari V, et al. Ewing's sarcoma of scapula: a rare entity. *BMJ Case Rep*. 2011 10; 2011:bcr0220113810. doi: 10.1136/bcr.02.2011.3810
- Delattre O, Zucman J, Plougastel B, et al. Gene fusion with an ETS DNA-binding domain caused by chromosome translocation in human tumours. *Nature*. 1992; 359(6391):162-165. doi: 10.1038/359162a0
- Sorensen PH, Triche TJ. Gene fusions encoding chimaeric transcription factors in solid tumours. *Semin Cancer Biol*. 1996; 7(1):3-14. doi: 10.1006/scbi.1996.0002
- Hoorneborg D, Veltman ES, Oldenburger F, Bramer JA, Schaap GR. A patient with scapular Ewing sarcoma; 5-year follow-up after extracorporeal irradiation and re-implantation of the scapula, a case report. *J Bone Oncol*. 2013; 2(1):30-32. doi: 10.1016/j.jbo.2012.12.002
- Gibbons CL, Bell RS, Wunder JS, et al. Function after subtotal scapulectomy for neoplasm of bone and soft tissue. *J Bone Joint Surg Br*. 1998; 80(1):38-42. doi: 10.1302/0301-620x.80b1.8183
- Mavrogenis AF, Mastorakos DP, Triantafyllopoulos G, Sakellariou VI, Galanis EC, Papagelopoulos PJ. Total scapulectomy and constrained reverse total shoulder reconstruction for a Ewing's sarcoma. *J Surg Oncol*. 2009; 100(7):611-615. doi: 10.1002/jso.21340
- Waqar SH, Zahid MA. Ewing's Sarcoma in Scapular Region. *APSP J Case Rep*. 2011;2(3):22.
- Iwamoto Y. Diagnosis and treatment of Ewing's sarcoma. *Jpn J Clin Oncol*. 2007; 37(2):79-89. doi: 10.1093/jjco/hy1142
- Schaeffers J, Vervloessem D, De Roover D, De Praeter M, van der Werff Ten Bosch J, van den Akker M. Soft tissue swelling in children: case report, differential diagnosis, and diagnostic delay. *Clin Case Rep*. 2016; 4(7):643-646. doi: 10.1002/ccr.3.585
- Newman EN, Jones RL, Hawkins DS. An evaluation of [F-18]-fluorodeoxy-D-glucose positron emission tomography, bone scan, and bone marrow aspiration/biopsy as staging investigations in Ewing sarcoma. *Pediatr Blood Cancer*. 2013; 60(7):1113-1117. doi: 10.1002/pbc.24406
- Clarke A, Dewnany G, Neumann L, Wallace WA. Glenothoracic fusion. An adjunct to radical scapulectomy. *J Bone Joint Surg Br*. 2004; 86(4):531-535.

Conclusion

Ewing's sarcoma family of tumors of the scapula is very rare in children and only several cases have been described in the literature so far. Tumor confined deep within muscles around the scapula may grow significantly before the onset of symptoms. Furthermore, symptoms may be ignored by patients or misinterpreted by doctors, and attributed to benign conditions such as overuse syndrome, trauma or infection, leading to a delay in diagnosis and an increase in the risk for the development of metastasis. Anyone to whom a young child or adolescent presents with the pain in the shoulder should be aware of the possibility that ESFT may be the cause of symptoms, especially if the pain is constant, and appears at night. The best option is to refer such a patient to a specialized center where a complete diagnostic workup could be promptly accomplished. Early diagnosis, current multimodal chemotherapy accompanied with surgical resection and/or radiation therapy may improve the prognosis of the patients with ESFT of the scapula. Limb salvage and reconstructive procedures to preserve shoulder function should be preferred surgical options whenever possible.