

## Case Report

## ORTHODONTIC-SURGICAL TREATMENT OF CLASS III MALOCCLUSION (HYPOPLASIO MAXILLAE) A CASE REPORT

Tatjana Perović<sup>1,2\*</sup>, Zoran Pešić<sup>1,3</sup>, Ilija Aleksić<sup>4</sup>, Julija Radojičić<sup>1</sup>, Zorica Blažej<sup>2</sup>

<sup>1</sup>Faculty of Medicine, University of Niš, Serbia

<sup>2</sup>Dental Clinic, Department of Orthodontics, Niš, Serbia

<sup>3</sup>Dental Clinic, Department of Maxillofacial Surgery, Niš, Serbia

<sup>4</sup>Independent dental technician

**Abstract.** Establishment of a treatment plan is based on efficiency and easy application by the clinician and acceptance by the patient. Treatment of patients with Class III malocclusion (hypoplasio maxillae) might require orthognathic surgery, especially when the deformity is severe, with a significant impact on facial esthetics. We report here the case of a 16-year-old boy who had a skeletal Class III malocclusion, leading to remarkable deviation of the maxillary midline; this was his chief complaint. Treatment included rapid maxillary expansion followed by leveling, alignment, correction of compensatory tooth positioning, and orthognathic surgery to correct the skeletal Class III malocclusion because of the severe maxillary deficiency. This treatment approach allowed correction of the maxillary dental midline discrepancy to the midsagittal plane and establishment of good occlusion and optimal esthetics.

**Key words:** class III malocclusion, hypoplasio maxillae, orthognathic surgery

### Introduction

Class III malocclusions represent complex irregularities, which can be of a dentoalveolar or skeletal nature. Skeletal class III malocclusions can be presented as false mandibular prognathism (hypoplasio maxillae), or real mandibular prognathism. Not so rarely, there is a combination of these two conditions, which additionally complicates the already existing difficult status of a dentofacial deformity and its therapy. Its frequency is different and it has racial distinctions: in white race it ranges from 1% to 5%, in yellow race from 9% do 19%, whereas in Latin population it is around 5% [1].

The ethology of this group of deformity is mostly hereditary but there are also some nonhereditary factors (e.g. oral respiration) which affect the deterioration of the existing intermaxillary ratio [1–3]. A therapy may go two ways:

- dentoalveolar camouflage- if there is not overexposed skeletal discrepancy, in which case only orthodontic therapy is applied without the correction of basal jaw ratio [3, 4];
- Combined surgical and orthodontic therapy, whereby the satisfying leveling of tooth arches is achieved by

presurgical orthodontic treatment, and the optimal intermaxillary ratio is achieved by osteotomy [5].

What represents a problem for most orthodontists is that the severity of deformity by the end of the growth cannot always be predicted with certainty, regardless of the number of applied analyses of types of growth [6]. Sometimes it can happen, especially in borderline cases, that camouflage therapy begins and by the end of the growth it is established that the existing state has deteriorated and the therapy ends in surgical intervention.

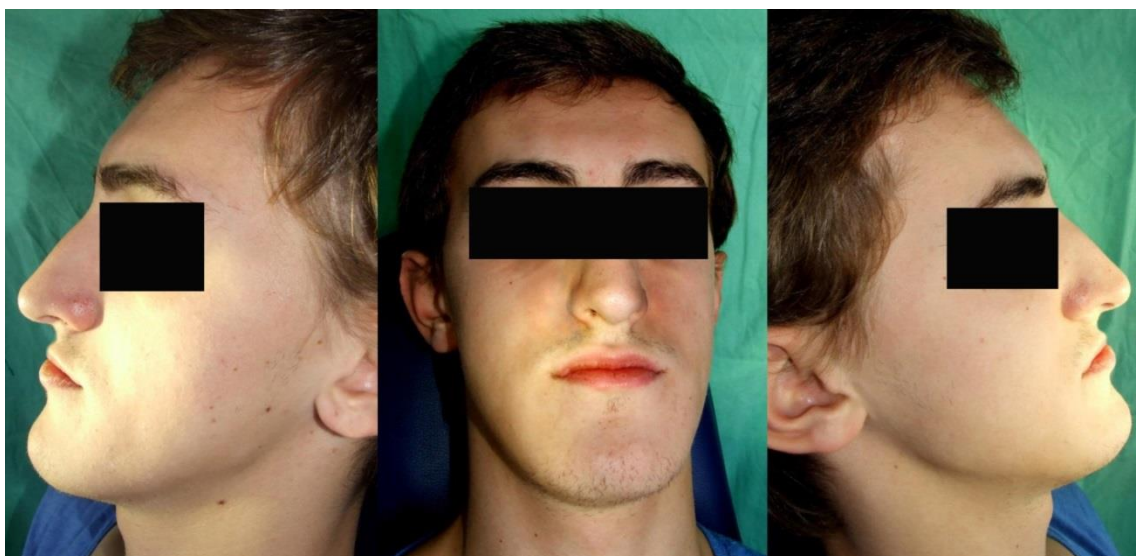### The review of the case

- The paper presents a combined, orthodontic and surgical therapy of a patient with a pronounced hypoplasia of the maxilla. A young man of 16 came to the Dental Clinic after two unsuccessful attempts to solve the problem. During that period the upper right second premolar was extracted, most likely due to the lack of space for a canine and lower first left molar. The anamnestic information is especially important and it indicated a long history of infections of upper respiratory pathways and adenectomy, which did not give the expected result (redirection of breathing)
- The outer clinical finding indicates a patient of asthenic constitution of a concave profile with a pronounced long adenoid face with characteristic paranasal depression, narrow alar base, with dark circles under the eyes, broad buccal corridors, hypotonic upper

\*Correspondence to: Tatjana Perović DDS, PhD  
16/22 Sestre Baković Street, 18000 Niš, Serbia  
Phone: 063 1045363

E-mail: tatjana.tanic@gmail.com

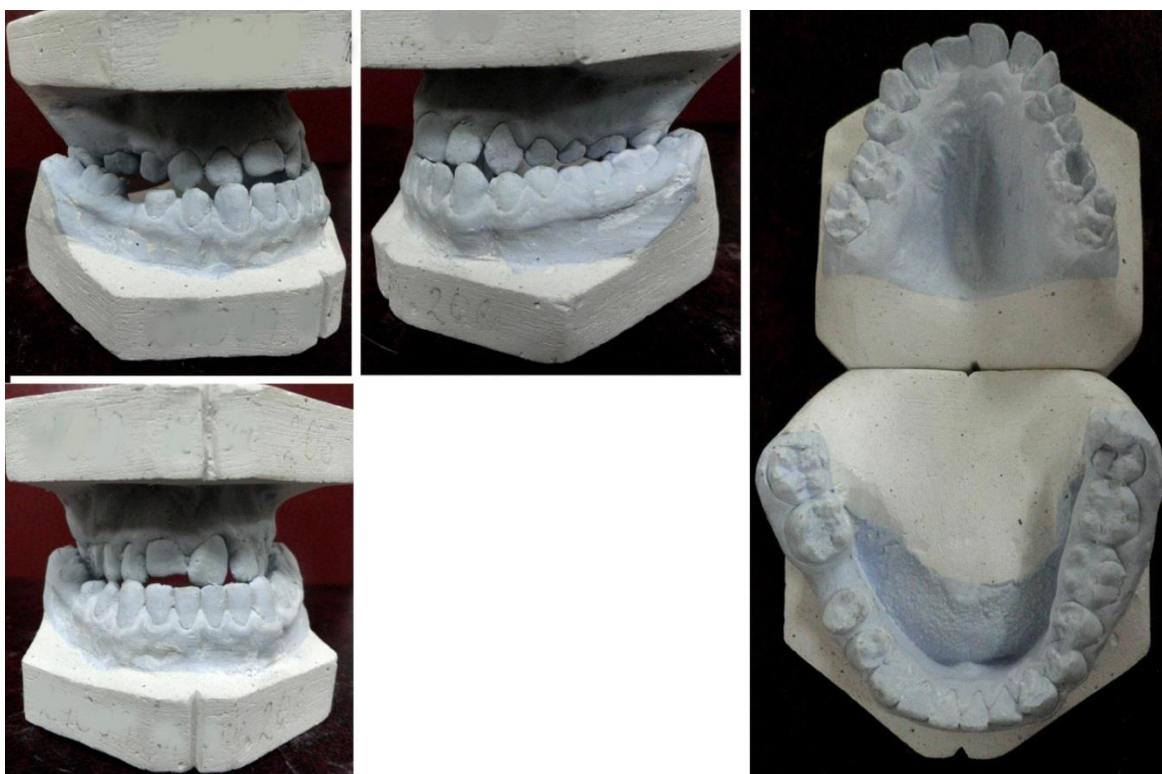Received January 3<sup>rd</sup>, 2016 / Accepted February 23<sup>rd</sup>, 2016



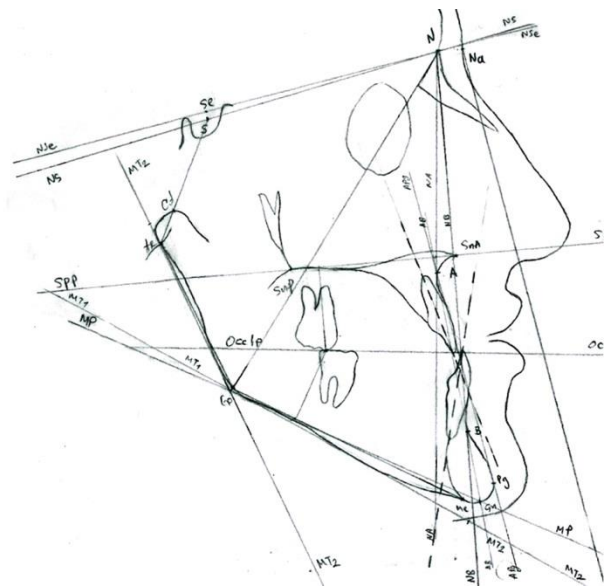
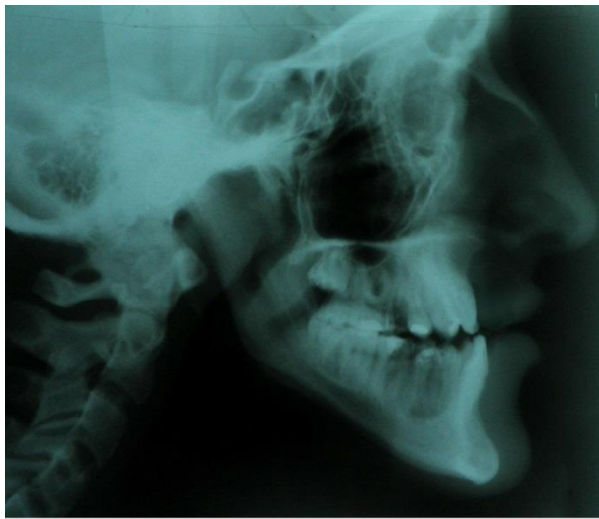**Fig. 1** Pretreatment extraoral photographs

lip... (Fig. 1) The functional finding is unsatisfactory in terms of breathing function, since the patient breathes through the mouth, regardless of the negative rhinological finding. He states that 'he does not get enough air when he breathes only through his nose'. The cutting and chewing of food is also difficult.

- The intraoral finding shows extremely narrow and asymmetrical upper dental arch, mildly crowded in the frontal part with a fractured incisal edge of the upper right central incisor. There is a very high, so called gothic palate. The lower dental arch is broad and long with the extracted right first molar. The occlusion of lateral teeth is in full III class. There is a severe degree of bilateral cross bite (the upper dental arch is 11mm narrower in the front and back width from the lower arch). There is a positive incisal step, and the incisors do not lap (Fig. 2).



**Fig. 2** Pretreatment models



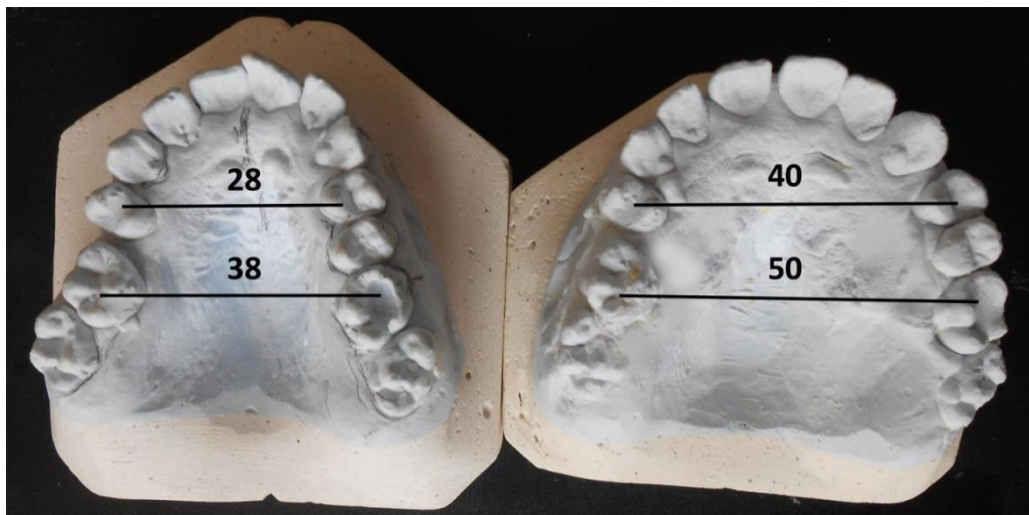**Fig. 3** Pretreatment cephalogram and cephalometric tracing

- The analysis of a profile cephalogram showed conspicuous maxillary retrognathism ( $SNA = 72^\circ$ ), followed by mild mandibular retrognathism ( $SNB = 78^\circ$ ). The sagittal intermaxillary angle ( $ANB$ ) of  $-6^\circ$  indicates skeletal relation of III class caused by hypoplasia of the maxilla. The sum of Bjork's polygon of  $401^\circ$  and the ratio of the front and back height of the face of 60% suggest hyperdivergent growth (Fig. 3).

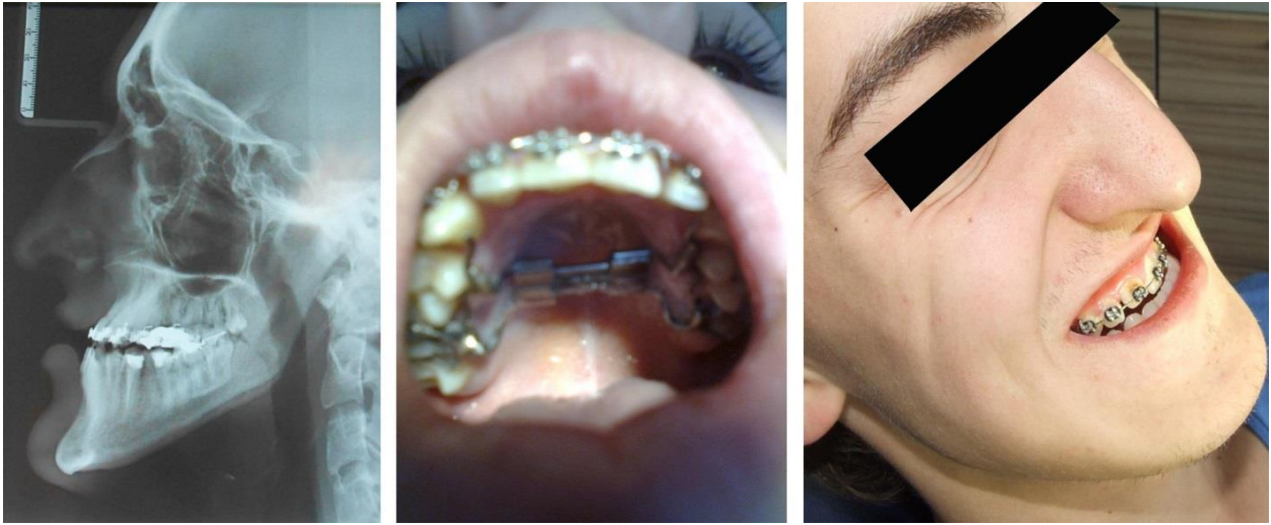
**The goals of therapy:**

1. Transversal alignment of maxillary with mandibular arch, using the method of midpalate distraction (rapid palatal expansion);
2. The leveling of dental arch with fixed appliances;
3. Surgical plan: Le Fort I osteotomy and forward placement of maxilla;
4. Long term retention plan.

In the plan of the therapy, the priority was given to rapid palatal expansion. For rapid palatal expansion, an appliance made on the basis of Rapid expander screw was used (manufacturer Leone, stock No A0620-13). The goal of this treatment was to transversally post-surgically align upper and lower dental arch. The alignment with retention was achieved in 12 months. Two months after placing an appliance for rapid palatal expansion (Fig. 4) an upper fixed appliance was placed (full arch, prescribed by Roth, slot 0,022") for the leveling of dental arch, for the purpose of pre-surgical preparation. The patient refused the application of a lower fixed appliance. He stated that for the mentioned period of palatal expansion his breathing "drastically improved and facilitated" which eliminated "hunger for oxygen", which is common in patients with hypoplasia of the maxilla. During this phase of therapy, positive incisal step increased and the bite slightly opened, which was expected due to posterior rotation and



**Fig. 4** Pretreatment upper model and upper model after rapid palatal expansion



**Fig. 5** Presurgical appearance and cephalograph

transferring cusps into a normal bucco-oral position (Fig. 5). After the removal of a fixed appliance, modified Hawley plate was used as a retention appliance and it was worn only during the night within the period of two years before surgery.

#### The description of surgery

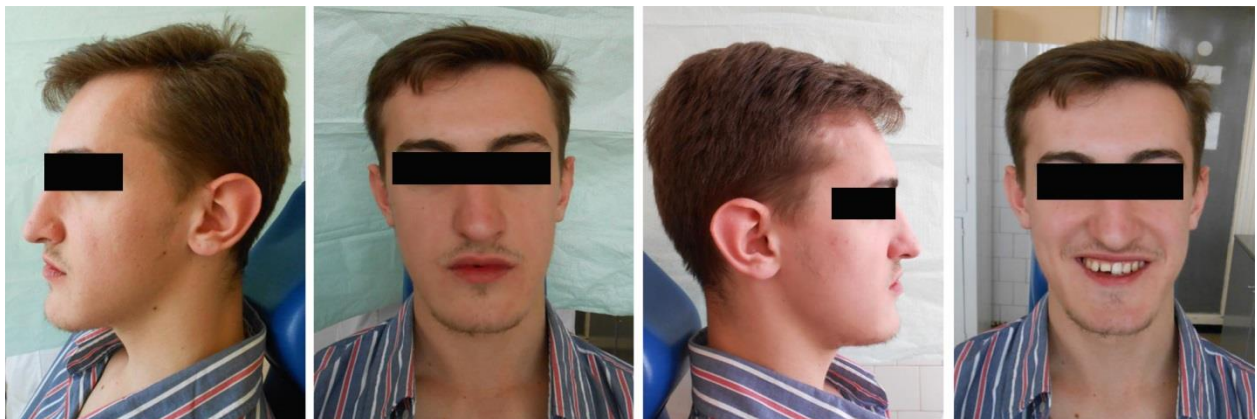Surgical procedure – After standard preoperative measures, surgical intervention was performed in general anesthesia. Air way intubation was transnasal. Incision and access through soft tissue was in horseshoe manner from first molar to first molar. Maxillary osteotomy at Le Fort I level was performed with preservation of palatal mucogingival pedicle. After osteotomy cuts and dissection of nasal spine from nasal mucosa as well as elevating nasal mucosa from a palatal, nasal septum and lateral nasal walls, nasal septum was separated from palatal segment. Pterygomaxillary disjunction was performed by curved chisel and disjunction and detachment of maxilla were finished. Then, maxillary segment was advanced in desired position checked by occlusion, as well as to mandibular

and to other parts of facial skeleton. Maxillary segment was fixated in desired position by using mini plates (Stryker Leibinger Midface mini plates). Mini plates were removed nine months after surgical intervention.

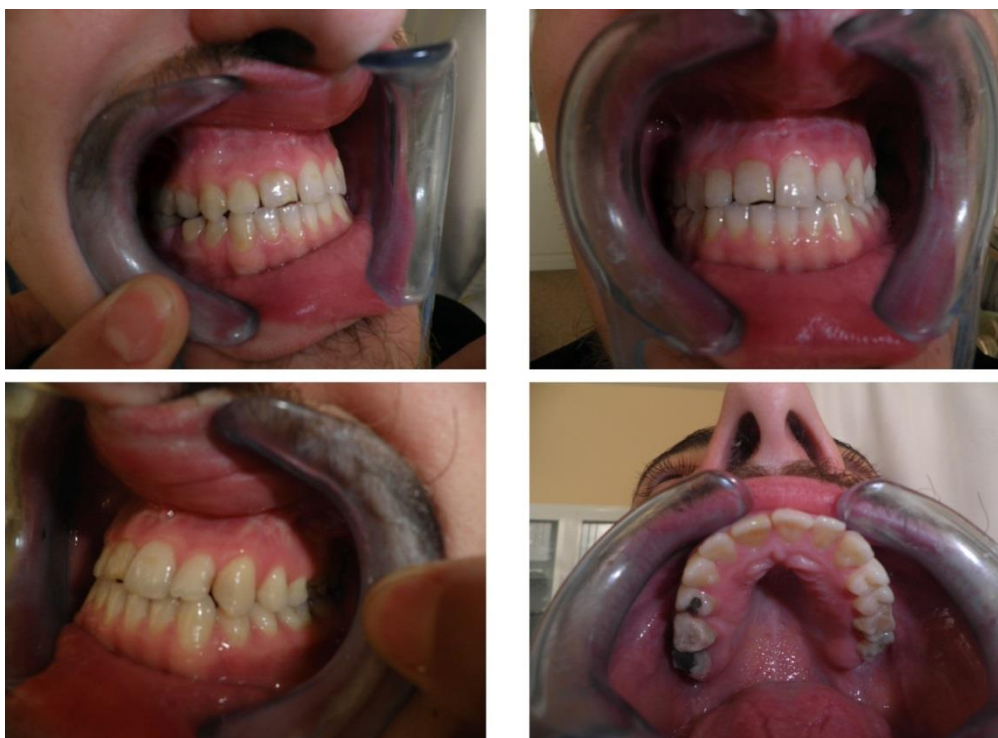Two years after the surgery, extraoral finding shows the improvement in facial visage with the normalization of facial features (Fig. 6). Nasal respiration is stabilized. Corrective occlusion was achieved intraorally in all three directions (Fig. 7, Table 1). The analysis of a profile cephalogram shows the improvement of dentoalveolar ratio (Fig. 8, Table 2).

**Table 1.** The values of the dentoalveolar parameters before and two years after whole treatment

Features	Pre-treatment	Post-treatment
Incisor relationship	reverse overjet	normal overjet
Overjet value	-2 mm	2 mm
Overbite	0 mm	2 mm
Midlines	shifted	co-incident
Left molar	class III	class I
Right molar	class III	class I
	(after reconstr.)	



**Fig. 6** Extraoral photographs, two years after surgery

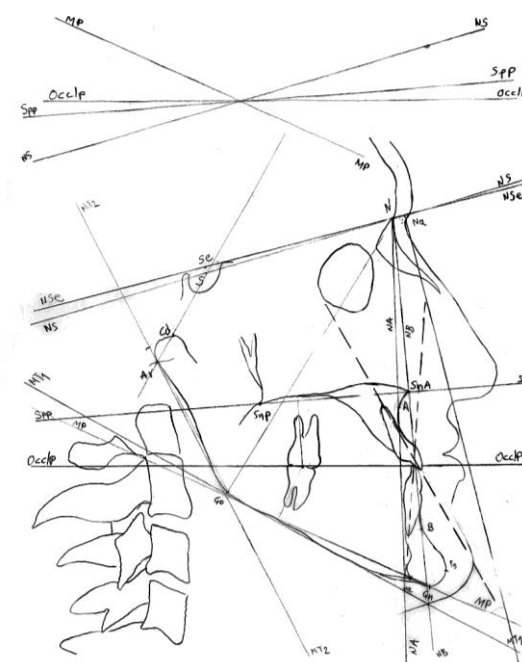
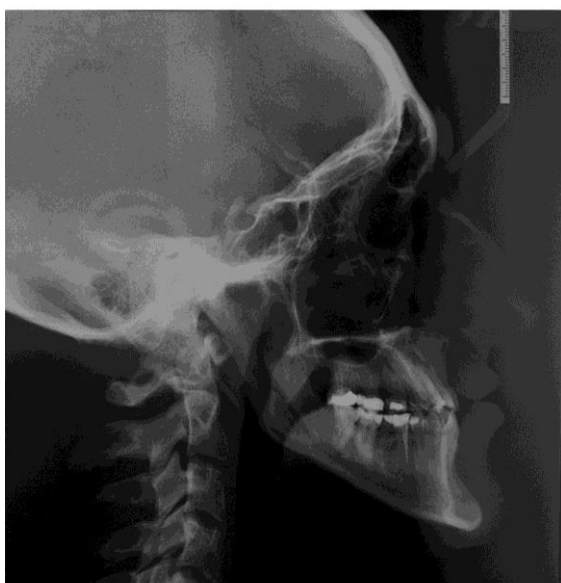

**Fig. 7** Intraoral photographs, two years after surgery

**Table 2.** The values of the SNA, SNB and ANB angles before and two years after whole treatment

Angles	(referent values)	Pre-treatment values	Post-treatment values
SNA	(82°)	72°	80°
SNB	(80°)	78°	78°
ANB	( 2°)	-6°	2°

SNA – position of the maxilla (normal, prognathic, retrognathic);  
 SNB – position of the mandible (normal, prognathic, retrognathic);  
 ANB – skeletal relationship between the maxilla and the mandible



**Fig. 8** Cephalograf and cephalometric tracing, two years after surgery

## Discussion

Hypoplasia of the maxilla represents a severe orthodontic problem, which is usually conspicuous in early childhood. It is considered to be primarily of hereditary ethology with strong effects on oral respiration [2]. With years, in most of the cases, the deformity progresses. Patients have aesthetic motivation to solve this problem [7], but functional difficulties should not be neglected as well. Aside from crowded upper tooth line, common effects of this condition are impacted canines [8, 9], asymmetrical upper tooth line [8], obligatory (uni- or bilateral) cross bite, often followed by apertognathia [10], sometimes turning of mandibula [11] which further complicates the therapy of the already existing condition.

The early therapy of hypoplasia of the maxilla has a great influence on the normalization of intermaxillary ratio, especially if facial mask by Delair is applied [12]. If this period is skipped, it is hard to camouflage this problem due to advancement of irregularities in the future, so this problem is usually treated orthodontically and surgically.

The motives for treating this type of deformity are often different. Patients usually cite aesthetics as the primary motivational factor. That was not the case with the portrayed patient. He cited functional discomforts (breathing, chewing) as primary. Facial aesthetics was not on his priority list. Still, after the completed treatment, he was thrilled with the change in the appearance of his face.

The main problem that appeared during the treatment was one-sided extraction of premolars in the upper jaw.

## References

1. Toffol LD, Pavoni C, Baccetti T, Franchi L, Cozza P. Orthopedic treatment outcomes in Class III malocclusion. A systematic review. *Angle Orthod* 2008; 78:561–573.
2. Stojanović LS, Mileusnić I, Mileusnić B, Cutović T. Orthodontic-surgical treatment of the skeletal class III malocclusion: a case report. *Vojnosanit Pregl* 2013; 70:215–20.
3. Bhandari PK, Anbuselvan G J. Nonsurgical management of class III malocclusion: A case report. *J Indian Acad Dent Spec Res* 2014; 1:35–38.
4. Satish HA, Daokar S, Gulati M. Different Non – Surgical Treatment Modalities for Class III Malocclusion. *IOSR-JMDS* 2013; 9:48–52.
5. Lamtiur PE. Orthodontic-surgical treatment of a severe class III malocclusion. *Dent J (Majalah Kedokteran Gigi)* 2013; 46: 229–234.
6. Benyahia H, Azaroual MF, Garcia C, Hamou E, Abouqal R, Zaou F. Treatment of skeletal Class III malocclusions: orthognathic surgery or orthodontic camouflage? How to decide. *Int Orthod* 2011; 9:196–209.
7. Lopez RG, Paz CS, Velazquez SS. Correcting a class III malocclusion with presurgical orthodontics and oblique ramus osteotomy. *Case Report. Revista Mexicana de Ortodoncia* 2014; 2:120–127.
8. Janson M, Janson G, Santana E, de Castro RC, de Freitas MR. Orthodontic-surgical treatment of Class III malocclusion with extraction of an impacted canine and multi-segmented maxillary surgery. *Am J Orthod Dentofacial Orthop* 2010; 137:840–849.
9. Mittal SK, Sharma R, Singla A, Grover V. Orthodontic-surgical correction of class III malocclusion with bilateral maxillary impacted canines. *J Innov Dent* 2011; 1(2).
10. Paraschivescu EG, Szuhaneck C. Surgical-orthodontic treatment in Class III skeletal anomalies. *Proceedings of the World Medical Conference 2011: 227–230.*
11. Bergamo AZ, Andruccioli MC, Romano FL, Ferreira JT, Matsumoto MA. Orthodontic-surgical treatment of Class III malocclusion with mandibular asymmetry. *Braz Dent J* 2011; 22:151–156.
12. Glišić B, Šćepan I, Nikolić Z, Đorđević D. Changes in position and relationship between jaws in children treated with Delair's mask. *Stom Glas S* 2004; 51:177–182. (in Serbian)
13. Kaán M. Unilateral space-creating extraction in orthodontics. *Fogorv Sz* 1994; 87:337–343. (in Hungarian)
14. Melgaço CA, Columbano Neto J, Jurach EM, Nojima Mda C, Sant'Anna EF, Nojima LI. Rapid maxillary expansion effects: an alternative assessment method by means of cone-beam tomography. *Dental Press J Orthod.* 2014; 19:88–96.

Such an asymmetrical dental arch compromised all the phases of therapy. First of all, it is hard to make an appliance for rapid palatal expansion if there is not an adequate number of lateral teeth on both sides. During the phase of expansion, asymmetrical expanding can easily develop due to the lack of reciprocity on the left and right side. Luckily, that did not happen here.

During the leveling of tooth line with a fixed appliance, the lack of one premolar leads to disbalance inside dental arch so that the planned corrective leveling of tooth arch remains at the level of compromise. Over time, this can lead to early contact and compromise the results of the entire therapy. For the mentioned reasons, the symmetry of dental lines should be imperative in orthodontic therapy, whenever it is possible [13, 14].

## Conclusion

Surgical-orthodontic treatment is sometimes the only option for achieving an acceptable occlusion and a good esthetic result in a patient with Class III dentofacial deformity. A correct diagnosis and planning as well as an appropriate execution of the treatment plan are determining factors for achieving success and long-term stability. It should be performed by a multidisciplinary team to ensure a satisfactory outcome.

**Acknowledgements:** The Authors are grateful to Dr Vasilija Teoharidu for technical support.