

Original Article

MODERN MANAGEMENT OF THYROGLOSSAL DUCT CYST

Mila R. Bojanović^{1,2}, Aleksandar Lj. Bojanović³, Miško Živić^{1,2}, Marko V. Lazović⁴, Mihajlo A. Bojanović¹

¹Faculty of Medicine, University of Niš, Serbia

²ENT Clinic Niš, Clinical Center Niš, Serbia

³Center of Radiology, Clinical Center Niš, Serbia

⁴Clinic of Cardiology, Clinical Center Niš, Serbia

Abstract. Thyroglossal duct cysts (TGCs) represent the most common congenital anomaly of the neck (7% of the population). They account for 2–4 % of all neck masses, and 70% of congenital neck abnormalities. Over half of cases are present in the first decade of life but they may also be seen in adults. Pyramidal lobe of the thyroid is the most common remnant of the thyroglossal tract and if no other thyroid tissue is identified, patients require lifelong replacement therapy after removal. TGCs arise from a persistent epithelial tract formed with the descent of the thyroid from the foramen caecum to its final position in the front of the neck. This duct obliterates early in fetal life. The duct so formed can rise in sinuses, fistulae or cysts. Symptoms can arise from the swelling itself or from complications, the most significant of which is infection. Surgical treatment of choice for TGCs is Sistrunk operation which includes dissection of the hyoid bone to the base of the tongue. Cancer has been reported in a small number of patients in whom the cyst is not removed until adulthood. Further studies are required to promote and establish novel treatment techniques, especially for recurrent cases.

Key words: thyroglossal duct cyst, diagnosis, treatment.

Introduction

Thyroglossal duct cysts (TGCs) represent the most common congenital anomaly of the neck (7% of the population). They account for 2–4 % of all neck masses, and 70% of congenital neck abnormalities.

TGCs arise from a persistent epithelial tract formed with the descent of the thyroid from the foramen caecum to its final position in the front of the neck. This duct obliterates early in fetal life.

The duct so formed can rise in sinuses, fistulae or cysts.

Symptoms can arise from the swelling itself or from complications, the most significant of which is infection [1–8].

Objective

To review and discuss the management options of thyroglossal duct cysts.

Methods

Analysis of databases was performed to identify the relevant articles following a thematic qualitative

analysis. Due to the variability of treatments along with the scarce amount of evidence, neither a formal systematic review nor a meta analysis were considered to be manageable. A qualitative analysis using a common thematic coding was performed instead, and clinical narrative review is presented.

Histology

Thyroglossal duct cyst is a well defined cyst with an epithelial lining composed of either squamous or respiratory epithelium.

There can sometimes be an island of thyroid tissue lying in the walls of the cysts. Thompson et al. reported that thyroid gland tissue is identified in 71 % of cases (0.45 cm mean size), although not limited to the cyst wall, but present in the surrounding soft tissues. Cysts are filled with mucoid or muco-purulent material depending on whether the cyst has been infected.

Types of Thyroglossal Duct Cysts

- Infrahyoid type – 65% and is mostly found in the paramedian position.
- Suprahyoid type – nearly 20% and is positioned in the midline.
- Juxtahyoid cyst – 15%.
- Intralingual location – 2%.
- Suprasternal variety – 10% of cases.
- Intralaryngeal – very rare.

*Correspondence to: Mila R. Bojanović, MD, PhD

Faculty of Medicine, University of Niš

81 Dr. Zoran Djindjić Blvd, 18000 Niš, Serbia

Phone: +381 64 2022884

E-mail: milabojanovic@yahoo.com

Received June 17th, 2016, accepted for publication July 16th, 2016

Embriology

The thyroid gland, although situated in the lower position of the neck around the trachea, originates in the mouth at the back of the tongue and then moves down the neck during development [1–5]. As the thyroid gland moves down to its normal position, there is connection to the base of the tongue (Fig. 1). That should disappear by the time the thyroid reaches its final position. If it does not, there may be a persistent hallow tube that may allow accumulation of mucoid material and the formation of a cyst at the end.

This is known as a thyroglossal duct cyst. Frequently this is noted soon after a cold when there has been swelling of the tonsils and others lymphoid tissue of the throat [7–9].

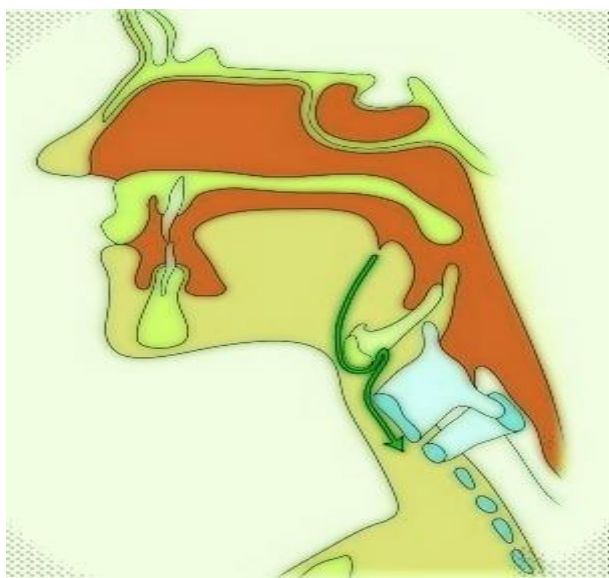


Fig. 1 Thyroglossal duct

Diagnosis

Approximately three-quarters of thyroglossal duct abnormalities present as cysts, whereas 25% present as a draining sinus on the skin. A sinus occurs as a result of infection (in the cyst) and rupture onto the chin with persistent drainage. The cysts are generally asymptomatic and are noticed by the family as a soft swelling under the skin over the area of the hyoid bone, a floating bone in the upper neck to which the tongue muscles are partially attached.

TGCs are usually single, smooth and 1–3 cm in size and move when the patient swallows or protrudes the tongue. The other causes for masses in this area of the neck include abnormally located thyroid tissue, lymph nodes, and dermoid cyst.

Imaging

X-rays are not usually needed as the diagnosis is frequently made by examining the mass. Thyroid scanning is not generally necessary but is reserved for patients who have either no detectable thyroid tissue in the neck on examination, or who following surgery have thyroid tissue noted within the surgical specimen. The tissue in this abnormal location is sometimes removed, and if no other thyroid tissue is identified, patients require lifelong replacement therapy [10–12].

They can be diagnosed with multiple imaging modalities including ultrasound (US), computed tomography (CT) and magnetic resonance imaging (MRI).

Ultrasound and CT are radiologic tools of choice. US is the gold standard and it can distinguish between solid and cystic components (Fig. 2).

CT and contrast CT (MSCT) may reveal a well circumscribed cystic lesion, 2–4cm in diameter with capsular enhancement [12].

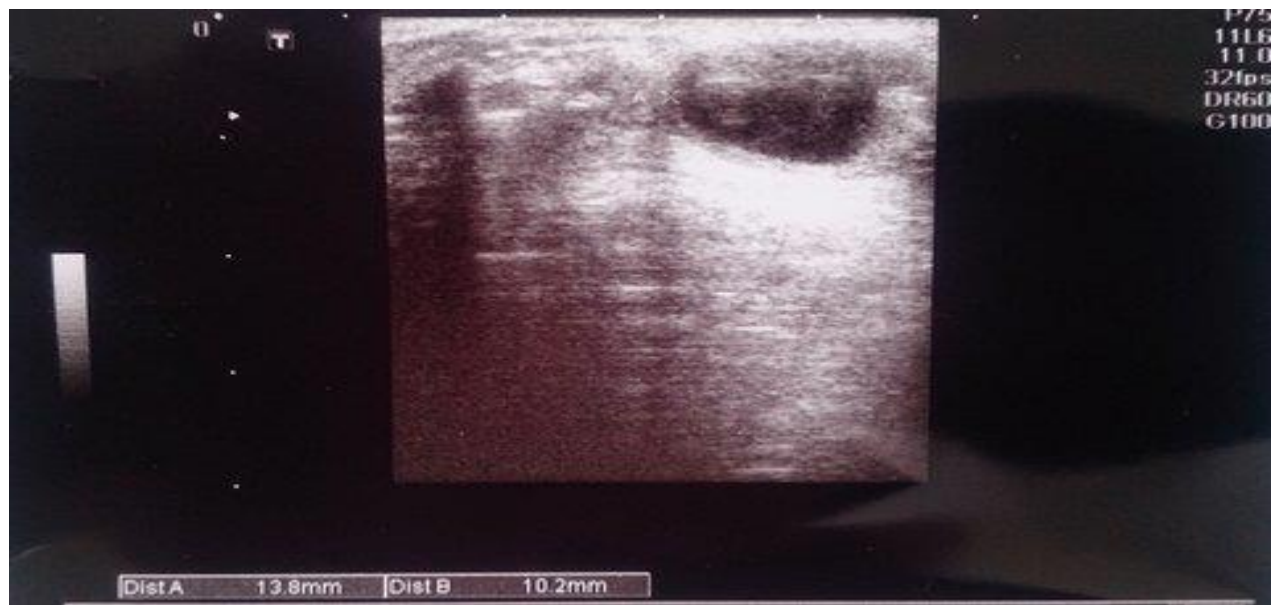

Fig. 2 Ultrasound of TGC, 21 years old female

Clinical Appearance

- Non tender and mobile masses.
- Infected cyst may manifest as tender mass with dysphagia, dysphonia, draining sinus fever and enlarging neck mass.
- Often appear with respiratory tract infection.
- Airway obstruction is possible, especially with intralingual cysts.
- The pathognomonic sign is that the cyst moves with tongue protrusion.

Differential Diagnosis

- Dermoid cyst
- Lymphadenopathy
- Sebaceous cysts
- Lymphatic malformations

Treatment

The treatment of choice for TGCs is complete removal of the cyst along with the extension to the back of the tongue. This is done in conjunction with removal of the central portion of the hyoid bone and is known as the Sistrunk procedure, named after the man who described it in 1920 (5). Delay in treatment often results in another infection which necessitates antibiotic therapy and delay of surgery until all the infection and inflammation are resolved (Fig. 3).

Removal is carried out under general anaesthesia. Approximately 10% of the cyst comes back and it is usually treated by a second removal. Recurrences are more common in patients who have had infected or previously drained TGCs [9,11,12].

Gioacchini et al. (2015) investigated 356 articles about TDGC and 24 were identified that satisfied selected criteria (a total of 1371 subjects) and concluded that a neck cyst mass is the main clinical presentation with a mean rate of 75%; that a most common

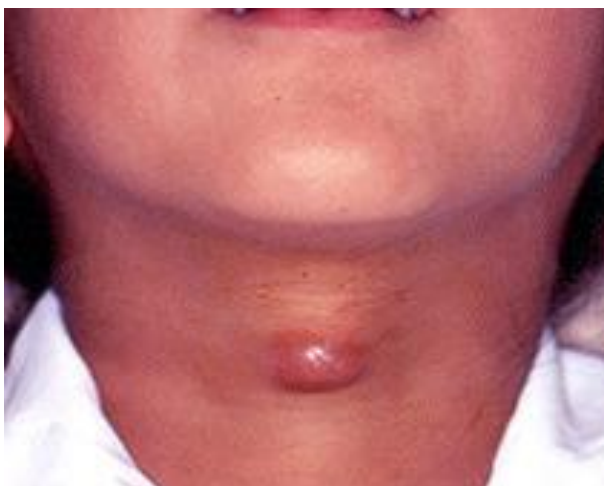

Fig. 3 TGC in 8 years old boy

complication after treatment is infection (4%) and that the mean overall recurrence was 11%. The Sistrunk procedure appears to be the better choice for the therapy of TGDCs to avoid recurrences. Further studies on larger cohorts of patients regarding the minimally invasive treatment options would be helpful to clarify and support their usefulness in selected cases [13].

Lendry et al. found that endoscopic removal with transoral laser microsurgery is a viable alternative to an external Sistrunk procedure in the case of an intralingual TGDC [14]

Huang et al. (2015) reported thirty-two patients from Beijing Tongren Hospital, Beijing, China, diagnosed with TGDCs who were selected. Seventeen patients with TGDCs were treated by traditional Sistrunk's surgery, and 15 patients underwent endoscopic cystectomy, and it was concluded that endoscope-assisted small-incision thyroglossal duct cystectomy is an efficient method. It causes smaller cosmetic defects and also reduces operative time. It will likely become the new standard procedure for patients with TGDCs [15].

Kim et al. stated that surgical treatment of midline TGDC via a retroauricular approach utilizing the robotic surgical system can be a technically doable and safe treatment option with outstanding cosmetic outcomes [16].

Many different operative methods have successfully treated recurrent thyroglossal duct remnants. To manage these challenging cases knowing the embryology, pathophysiology and applied anatomy is of paramount importance. Sistrunk procedure has the best cure rate.

Incomplete thyroglossal duct removal in the suprahyoid region mostly results in recurrences. The perihyoid, infrahyoid and tongue base are some other areas of recurrence. After a failed Sistrunk procedure, for management of recurrent disease, an extended or wide local incision is recommended: in the suprahyoid area including tongue base muscles and foramen cecum mucosa; removal of at least 2/3 of hyoid bone remnants, and a wide local incision of infrahyoid and the space posterior to the hyoid bone [17].

As mentioned above, many studies directed at the wider excision of the thyroglossal duct to completely excise the multiple and accessory tracts ("Christmas tree") that are present in recurrent lesions and authors proposed novel techniques: repeat or extended [18] Sistrunk procedure, en bloc neck dissection, suture-guided transhyoid pharyngotomy, and Koempel's suprahyoid technique. Even though this review reports a 100% success rate with the 2 latter procedures, authors state that further prospective studies are required [18,19].

Cancer has been reported in a small number of patients in whom the cysts are not removed until adulthood [6]. Brewis et al. concluded that pediatric surgeons did fewer investigations than ENT surgeons and tended to excise more of the thyroglossal tract. Review of the published work suggests that ultrasound scanning and Sistrunk procedure are the best management policy [3,5] (Fig. 4).

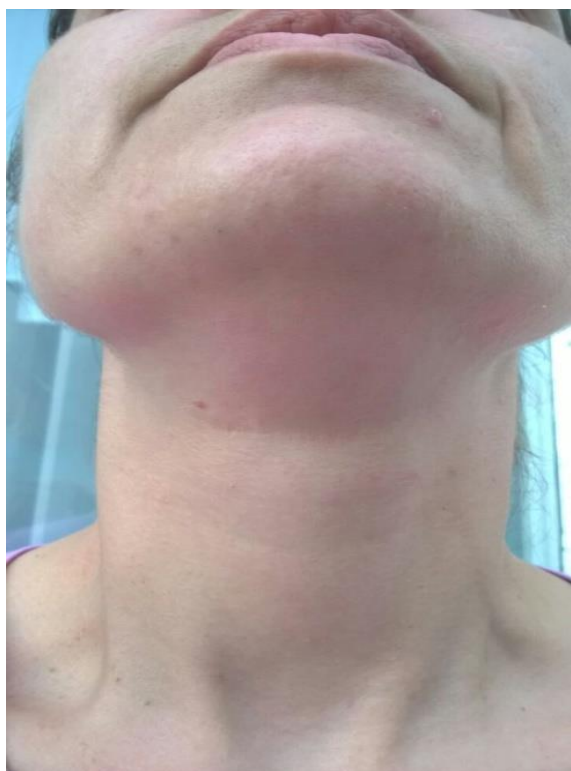

Fig. 4 Ten years after Sistrunk procedure for TGC in a young female, without recurrence and complication. Good cosmetic appearance

Although rare, multiple recurrences have also been reported usually requiring wider removal of tissue in the region of the remaining hyoid bone. Recurrence is the most common complication of treatment and is managed by central neck dissection.

Complications

Infection is probably the most common complication.

Local growth and invasion are extremely uncommon.

Carcinoma is very rare and occurs in about 1-2% of patients.

Thyroid ectopia – fewer than 5% of these cysts actually have ectopic thyroid tissue.

Conclusion

Surgical treatment of choice for TGCs is Sistrunk operation which includes dissection of the hyoid bone to the base of the tongue.

Less than 5% of these cysts actually have ectopic thyroid tissue.

Cancer occurs approximately in 1–2 % of TGCs in patients in whom the cyst is not removed until adulthood.

Further studies are required to promote and establish novel treatment techniques, especially for recurrent cases.

References

1. Deaver MJ, Silman EF, Lotfipour S. Infected thyroglossal duct cyst. *Western J Emerg Med* 2009;10:205.
2. Bhat SM. *SRB's Manual of Surgery*, 3rd edition. Jaypee Brothers Medical Publishers (P) Ltd: New Delhi, 2009; pp. 405–406.
3. Brewis C, Mahadevan M, Bailey CM, Drake DP. Investigation and treatment of thyroglossal cysts in children. *J R Soc Med* 2000; 93:18–21.
4. Huang L-D, Gao S-Q, Dai R-J, et al. Intra-thyroid thyroglossal duct cyst: a case report and review of literature. *Int J Clin Exp Pathol* 2015; 8:7229–7233.
5. Sistrunk WE. The surgical treatment of cysts of the thyroglossal tract. *Ann Surg* 1920; 71:121–122.
6. McNicoll MP, Hawkins DB, England K, Penny R, Maceri DR. Papillary carcinoma arising in a thyroglossal duct cyst. *Otolaryngol Head Neck Surg* 1988; 99: 50–54.
7. Milićević R, Kostić A, Bojanović M. Kongenitalne malformacije: teratogeneza, genetika i principi lečenja. In: Milićević R (ed) *Kongenitalne anomalije prednjeg trbušnog zida*, monografija. Medicinski fakultet u Nišu: Niš, 2007; pp. 11–29.
8. Karmakar S, Saha AM, Mukherjee D. Thyroglossal cyst: an unusual presentation. *Indian J Otolaryngol Head Neck Surg* 2013; 65:185–187. doi:10.1007/s12070-011-0458-5.
9. Thompson LD, Herrera HB, Lau SK. A clinicopathologic series of 685 thyroglossal duct remnant cysts. *Head Neck Pathol* 2016. [Epub ahead of print] DOI: 10.1007/s12105-016-0724-7
10. Weerakkody Y, Gaillard F. Thyroglossal duct cyst. *UBM Medica Network*. 2015; Retrieved from <http://radiopaedia.org>
11. Kepertis C, Anastasiadis K, Lambropoulos V, Mouravas V, Spyridakis I. Diagnostic and surgical approach of thyroglossal duct cyst in children: ten years data review. *J Clin Diagn Res* 2015; 9:13–15. doi:10.7860/JCDR/2015/14190.6969.
12. Soni S, Poorey VK, Chouksey S. Thyroglossal duct cyst, variation in presentation, our experience. *Indian J Otolaryngol Head Neck Surg* 2014; 66:398–400. doi:10.1007/s12070-014-0724-4.
13. Gioacchini FM, Alicandri-Ciuffelli M, Kaleci S, Magliulo G, Presutti L, Re M. Clinical presentation and treatment outcomes of thyroglossal duct cysts: a systematic review. *Int J Oral Maxillofac Surg* 2015; 44:119–126. doi: 10.1016/j.ijom.2014.07.007.
14. Landry AM, Cain RB, Patel AS, Hinni ML. Transoral laser microresection of thyroglossal duct cyst: a novel surgical approach. www.triomeetingposters.org/wp-content/uploads/2012/12/2-203.pdf
15. Zhigang H, Wei G, Bing Z, Xiaohong Ch. Minimally invasive endoscopic surgery of thyroglossal duct cysts. *J Laparoendosc Adv Surg Tech* 2015; 25: 892–896.
16. Kim CH, Byeon HK, Shin YS, Koh YW and Choi EC. Robot-assisted Sistrunk operation via a retroauricular approach for thyroglossal duct cyst. *Head Neck* 2014; 36:456–458. doi: 10.1002/hed.23422
17. P Hong. Management of recurrent thyroglossal duct remnants after Sistrunk procedure: a clinical narrative review of surgical approaches. *The Internet Journal of Otorhinolaryngology* 2012; 14:1–6.
18. Pastore V, Bartoli F. "Extended" Sistrunk procedure in the treatment of recurrent thyroglossal duct cysts: a 10-year experience. *Int J Pediatr Otorhinolaryngol* 2014; 78:1534–1536. doi: 10.1016/j.ijporl.2014.06.029.
19. Ibrahim FF, Alnoury MK, Varma N, Daniel SJ. Surgical management outcomes of recurrent thyroglossal duct cyst in children—A systematic review. *Int J Pediatr Otorhinolaryngol* 2015; 79:863–867. doi: 10.1016/j.ijporl.2015.03.019.