

## MOYAMOYA PHENOMENON IN SERBIAN POPULATION

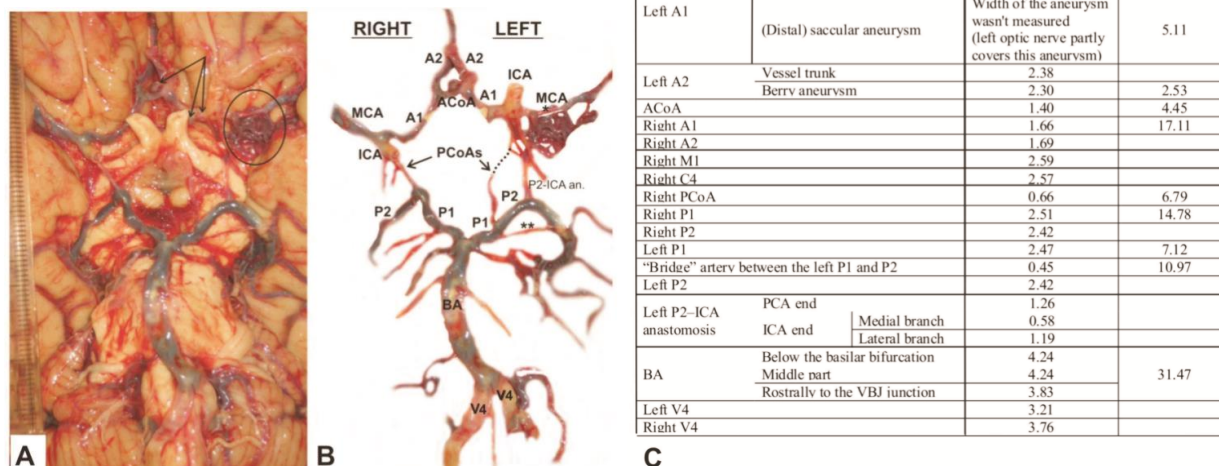
Aleksandar Kostić<sup>1</sup>, Milena Trandafilović<sup>2\*</sup>, Ivan Stojanović<sup>3</sup>University of Niš, Faculty of Medicine, <sup>1</sup>Clinic for Neurosurgery, <sup>2</sup>Department of Anatomy, <sup>3</sup>Institute for Forensic Medicine, Niš, Serbia

To the editor:

We want to provide a detailed description of the case of Moyamoya phenomenon that was recently noted in the paper about the morphology of cerebral arterial circles (CACs) in Serbian population [1]. We found that the first paper about Moyamoya phenomenon referring to Serbia was published almost twenty years ago [2].

The word “moyamoya”, taken from a Japanese dictionary, in translation means a puff of smoke; in scientific literature it refers to the network of fine collaterals around and distal to the CAC due to progressive unilateral (Moyamoya syndrome) or bilateral (Moyamoya disease) stenosis of the intracranial part of the internal carotid artery (ICA) and its proximal branches [3].

Moyamoya syndrome was found in a 55-years-old male, who died due to pulmonary thromboembolism.



**Fig. 1.** Arteries on the brain base of a male cadaver. **A**, Convoluted blood vessels (Moyamoya pattern) in the sphenoid part of the left middle cerebral artery (circle), and three aneurysms (arrows) in the left anterior cerebral artery. **B**, Brain arteries and persistent primitive anastomoses are marked on modified image. **C**, Outer diameters of brain arteries and anastomoses are noted in the table. C4, choroid and communicating subparts of the cerebral part of the internal carotid artery (ICA); M1, sphenoid part of the middle cerebral artery; \*stenosed M1 subpart; A1, precommunicating part of the anterior cerebral artery (ACA); A2, postcommunicating part of the ACA; ACoA, anterior communicating artery; PCoA, posterior communicating artery; P1, precommunicating part of the posterior cerebral artery (PCA); P2, postcommunicating part of the PCA; P2-ICA an., P2-ICA anastomosis; \*\*bridge artery between the left P1 i P2; BA, basilar artery; V4, intracranial part of the vertebral artery.

Correspondence to: Milena Trandafilović, MD  
Faculty of Medicine, Dept. of Anatomy,  
81 Dr Zoran Đinđić Blvd., 18000 Niš, Serbia  
Phone: +381 18 45 70 029 Fax: +381 18 423 87 70  
E-mail: mitra018@yahoo.com

The research of cadaveric brain vessels was performed at the Institute of Forensic Medicine in Niš during co-author's (MT) academic and postdoctoral studies. An approval for doctoral investigation was granted by the

Research Ethics Committee (No. 01-206-1) of our Faculty of Medicine. The vessels were photographed on the brain base; their outer diameters were studied from the digital images, using the ImageJ program (<http://rsb.info.nih.gov/ij/index.html>). Summarizing pathoanatomical findings, we will indicate six features: 1) a partial stenosis of the left middle cerebral artery (MCA) at its sphenoid part and a presence of a network of the MCA collaterals medially to the limen insulae; 2) the presence of three (one saccular and two berry) aneurysms in the left anterior cerebral artery (ACA); 3) the presence of atheromatous plaques in the basilar artery, and internal carotid and vertebral arteries; 4) the presence of a “bridge” artery between the left precommunicating (P1) and post-communicating (P2) parts of the posterior cerebral artery; 5) the presence of the left P2–ICA anastomosis; and 6) left-right caliber asymmetry of arteries on the brain base (Fig.1).

As cited by Scott and Smith [3], the incidence peaks were in five-year children and adults in their mid-40s and the incidence among all patients with Moyamoya in

Europe appears to be about 1/10 of that observed in Japan. Case reports in the Balkan journals were related to the case of Moyamoya disease in a 13 year-old girl in Serbia [2], and the case of Moyamoya syndrome of a 71-year-old male in Slovenia [4]. In a retrospective study by Borota et al. [5] over a period of 22 years in the former Yugoslavia, Moyamoya pattern of cerebral vessels was discovered only in 31 patients of both genders. We accepted the definitions of Moyamoya syndrome and Moyamoya disease given by Scott and Smith [3], although there were different diagnoses in cited cases [2,4], or Moyamoya modification [6]. However, there was an association of many vascular abnormalities in this, as well as in the cases of Moyamoya phenomena from the Balkan peninsula [4,5] to Japan [6], and beyond.

**Acknowledgments.** Contract grant sponsor: Ministry of Education, Science and Technological Development of Republic of Serbia (No: 41018).

## References

1. Vasović L, Trandafilović M, Jovanović I, et al. Morphology of the cerebral arterial circle in the prenatal and postnatal period of Serbian population. *Childs Nerv Syst* 2013; 29:2249–2261.
2. Vranješević D, Jović NS, Milovanović D, Đukić A. Unilateral Moyamoya disease associated with acrofacial vitiligo in a 13-year-old patient—case report. *Srp Arh Celok Lek* 1994; 122:234–236. (In Serbian)
3. Scott RM, Smith ER. Moyamoya disease and Moyamoya syndrome. *N Engl J Med* 2009; 360:1226–1237.
4. Zaletel M, Surlan-Popović K, Pretnar-Oblak J, Žvan B. Moyamoya syndrome with arteriovenous fistula after head trauma. *Acta Clin Croat* 2011; 50:115–120.
5. Borota L, Bajić R, Marinković S, Maksimović R, Marković Z, Kovačević M. The main epidemiological, clinical and morphological features of Moyamoya disease in Yugoslavia. *Clin Neurol Neurosurg* 1997; 99:S49–S53.
6. Komiya M, Nakajima H, Nishikawa M, et al. High incidence of persistent primitive arteries in Moyamoya and Quasi-Moyamoya diseases. *Neurol Med Chir (Tokyo)* 1999; 39:416–422.